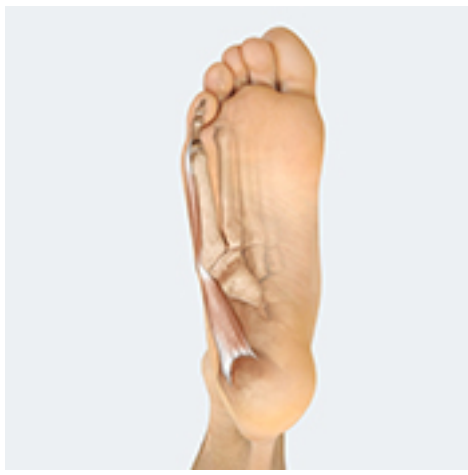
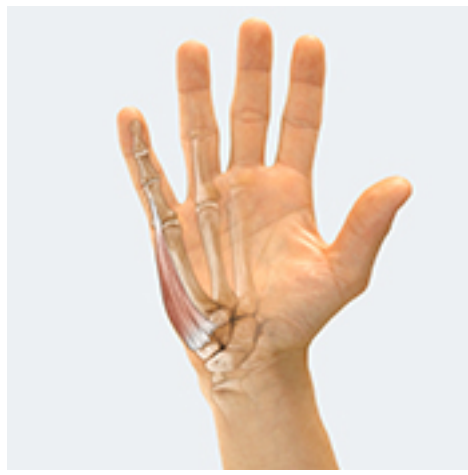
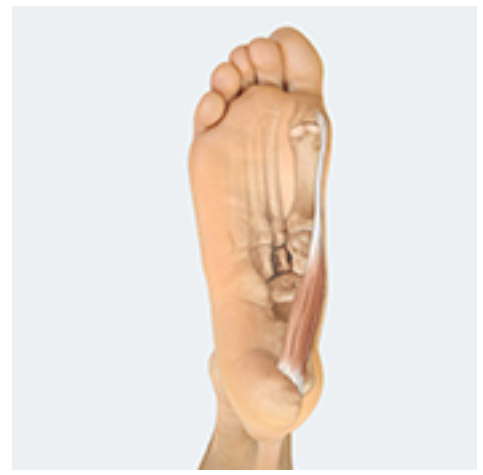

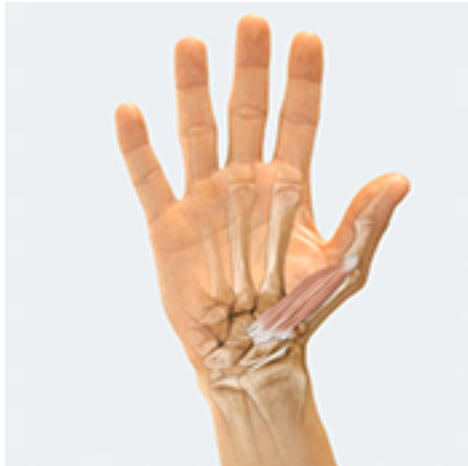m\_abductor\_digiti\_minimi\_pedis.tif



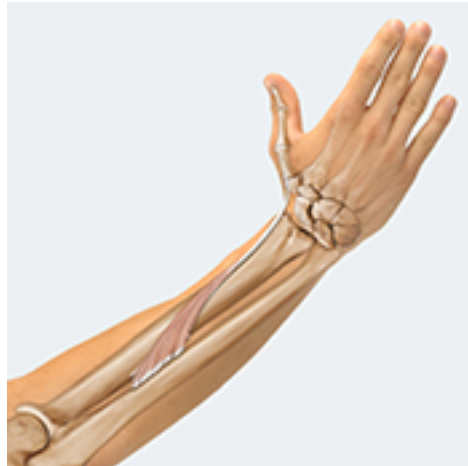m\_abductor\_digiti\_minimi.tif



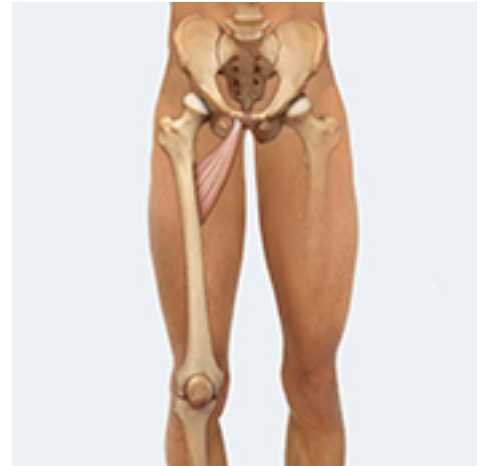m\_abductor\_hallucis.tif



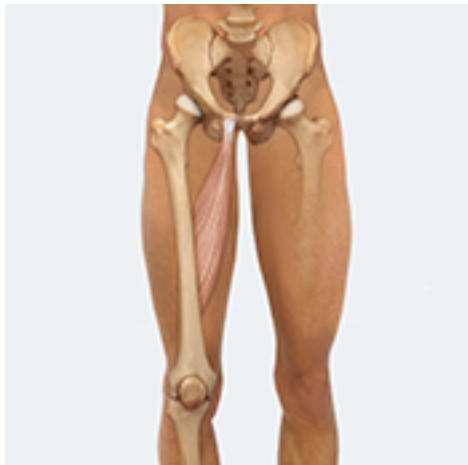m\_abductor\_pollicis\_brevis.tif



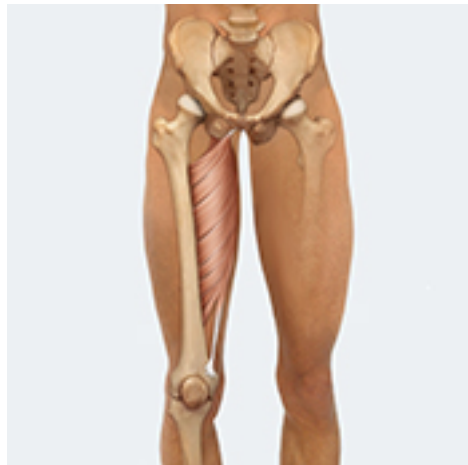
m\_abductor\_pollicis\_longus.tif



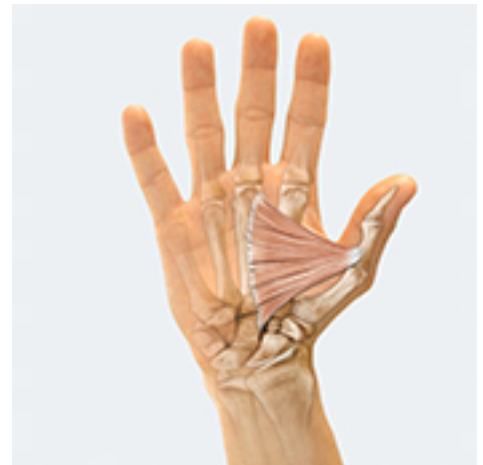m\_adductor\_brevis.tif



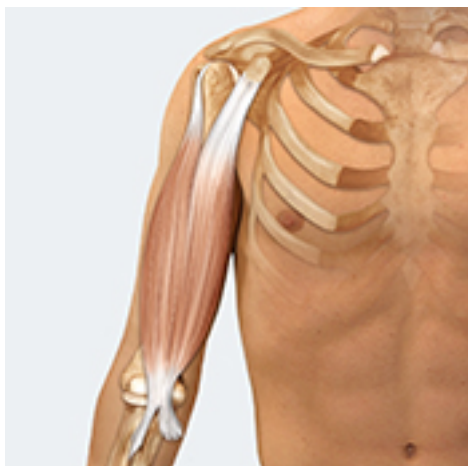
m\_adductor\_longus.tif



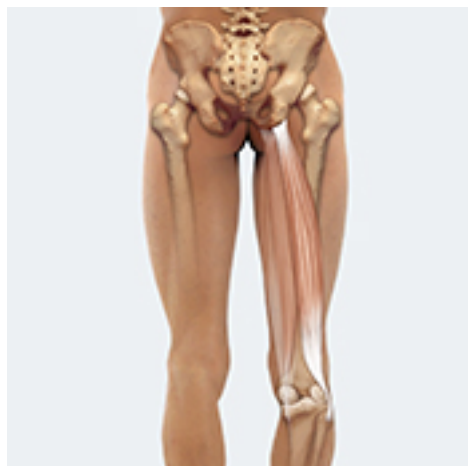
m\_adductor\_magnus.tif



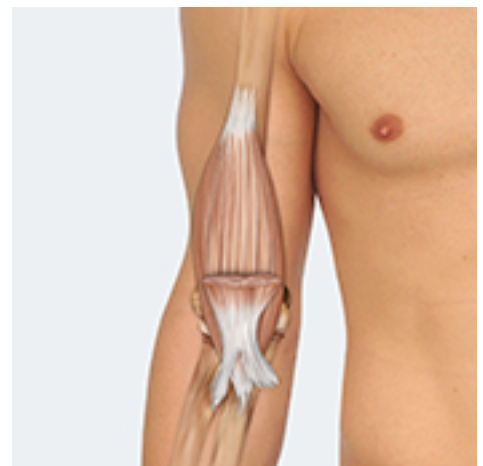
m\_adductor\_pollicis.tif



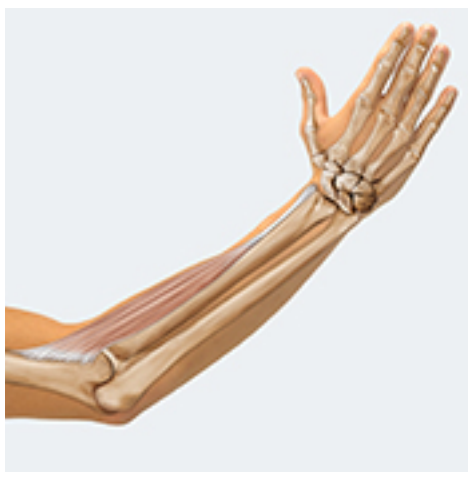m\_biceps\_brachii.tif



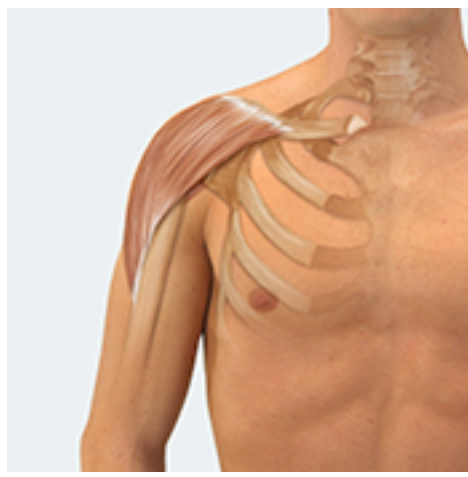m\_biceps\_femoris.tif



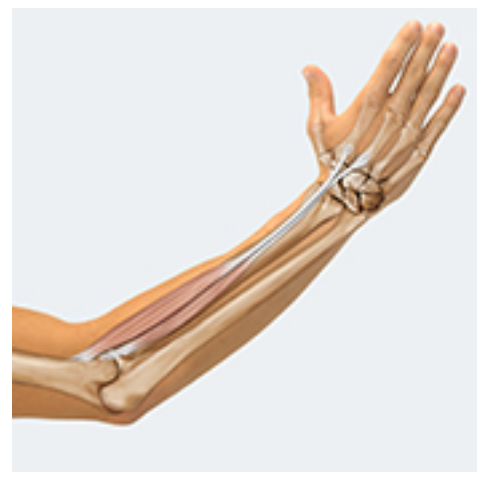m\_brachialis.tif



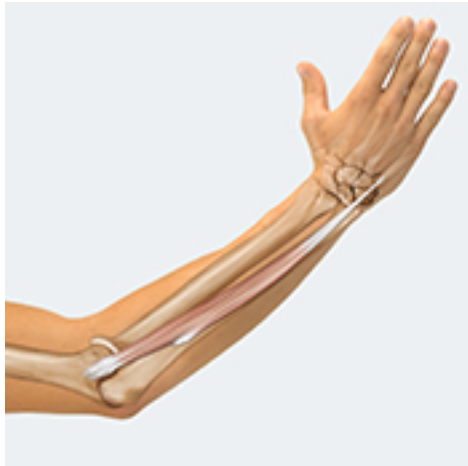m\_brachioradialis.tif



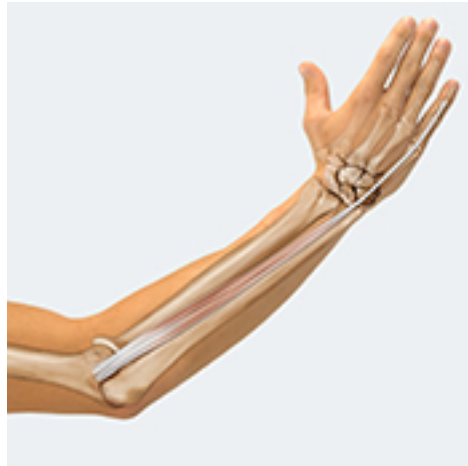m\_deltoides.tif



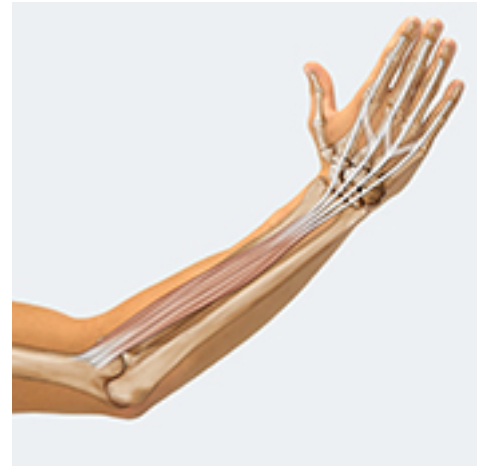m\_extensor\_carpi\_radialis\_longus\_brevis.tif



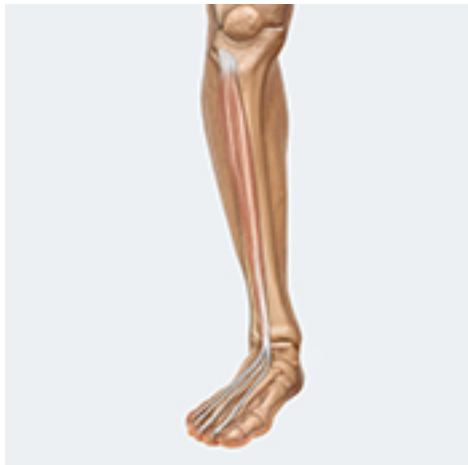m\_extensor\_carpi\_ulnaris.tif



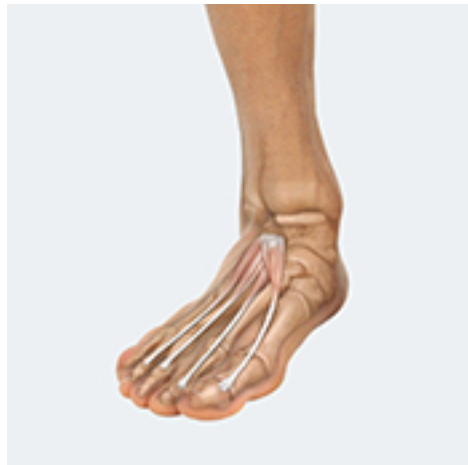m\_extensor\_digiti\_minimi.tif



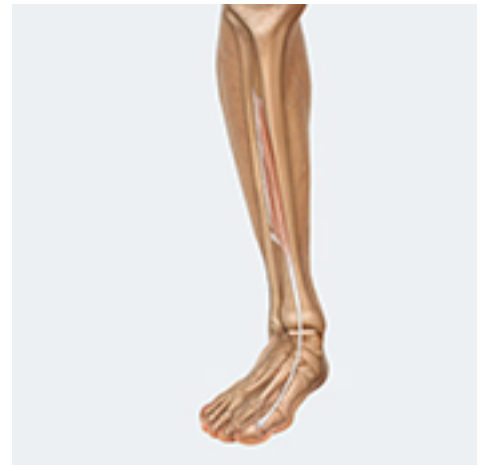m\_extensor\_digitorum\_communis.tif



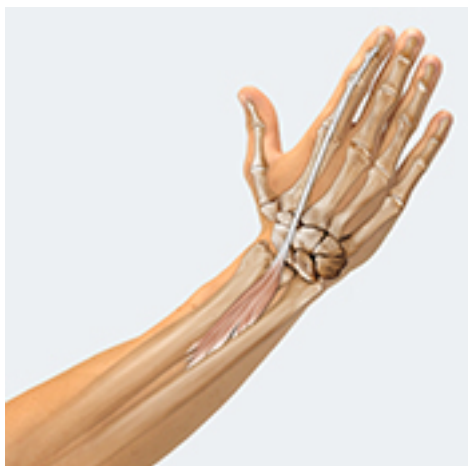m\_extensor\_digitorum\_longus.tif



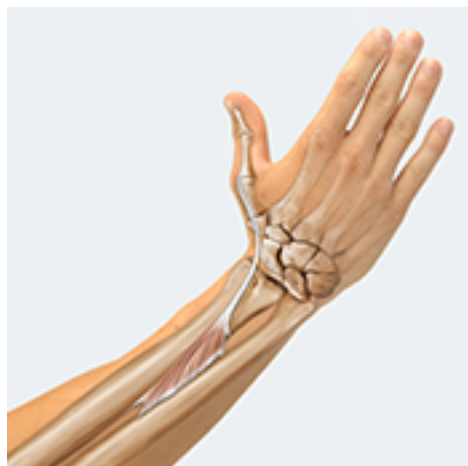m\_extensor\_hallucis\_brevis\_digitorum\_brevis.tif



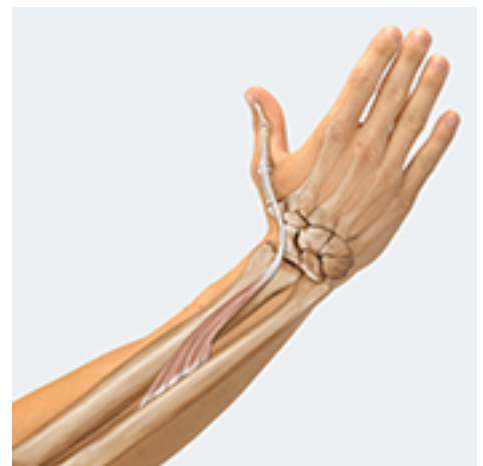m\_extensor\_hallucis\_longus.tif



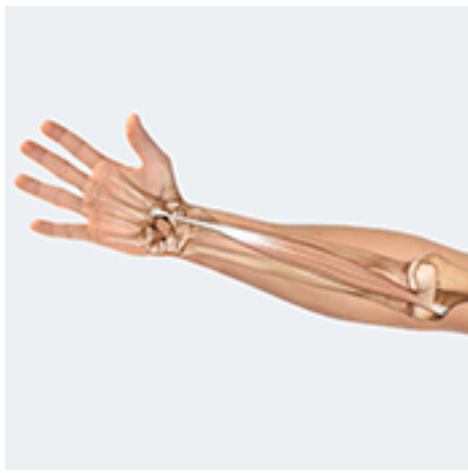m\_extensor\_indicis.tif



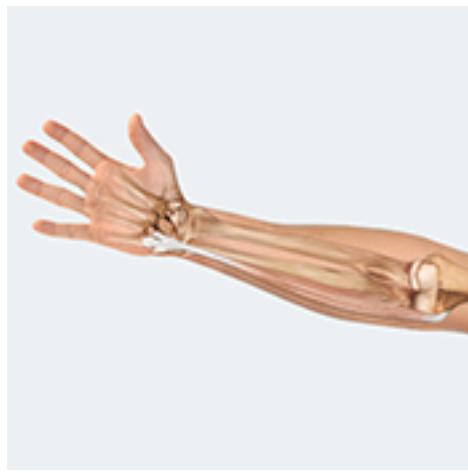m\_extensor\_pollicis\_brevis.tif



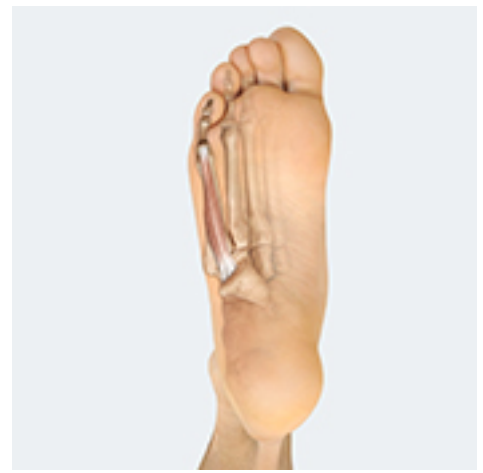m\_extensor\_pollicis\_longus.tif



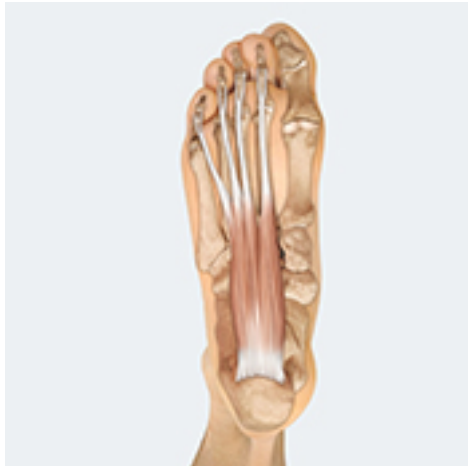
m\_flexor\_carpi\_radialis.tif



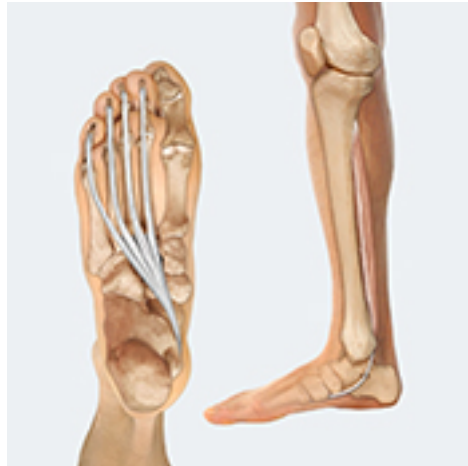m\_flexor\_carpi\_ularis.tif



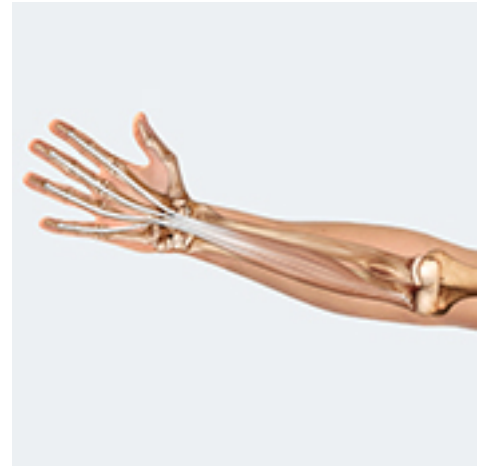
m\_flexor\_digiti\_minimi\_brevis\_pedis.tif



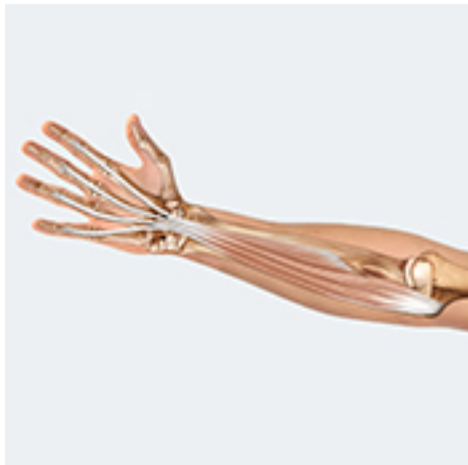
m\_flexor\_digitorum\_brevis.tif



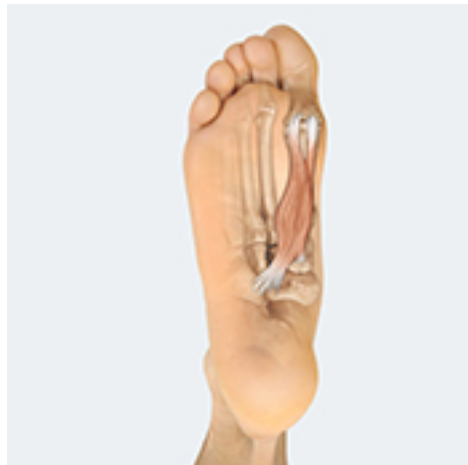
m\_flexor\_digitorum\_longus\_sehne.tif



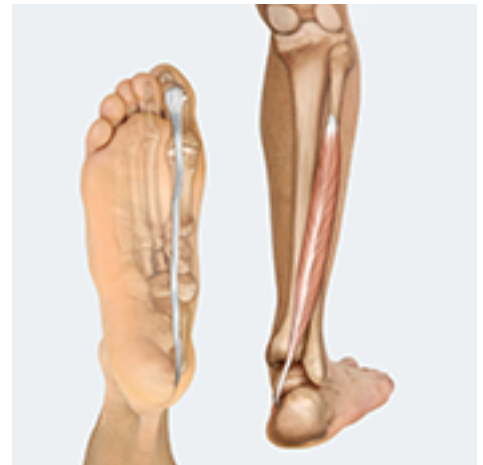m\_flexor\_digitorum\_profundus.tif



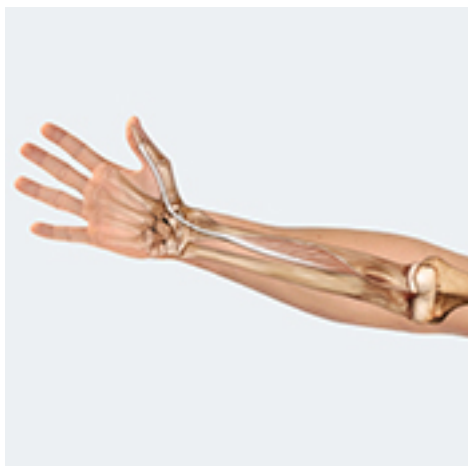
m\_flexor\_digitorum\_superficialis.tif



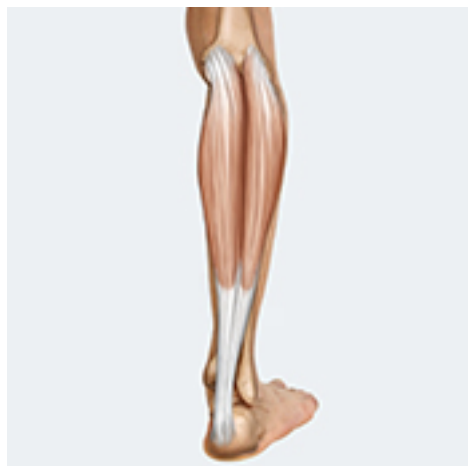
m\_flexor\_hallucis\_brevis.tif



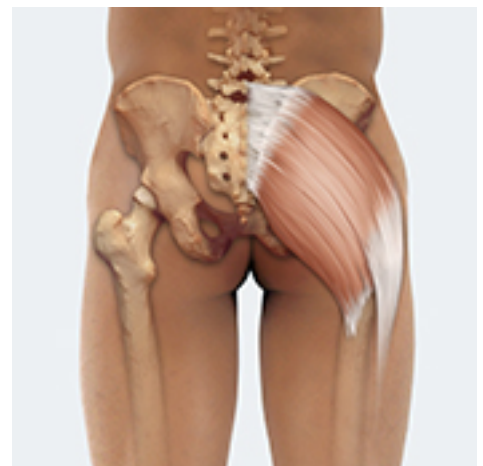m\_flexor\_hallucis\_longus\_sehne.tif



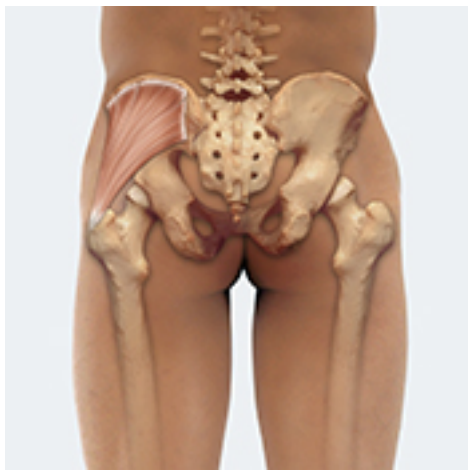m\_flexor\_pollicis\_longus.tif



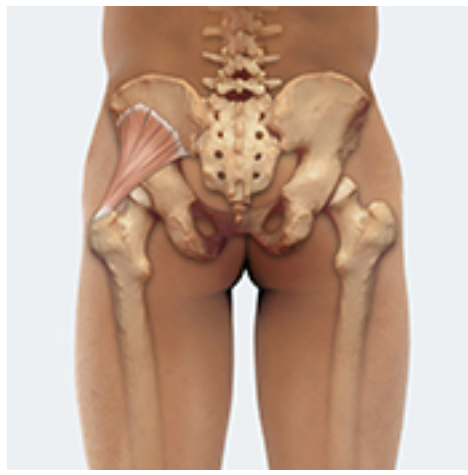m\_gastrocnemius.tif



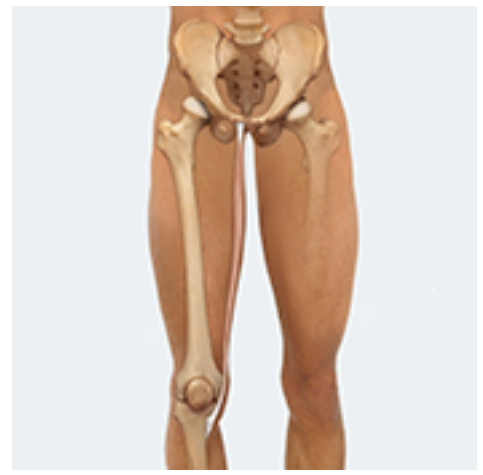m\_gluteus\_maximus.tif



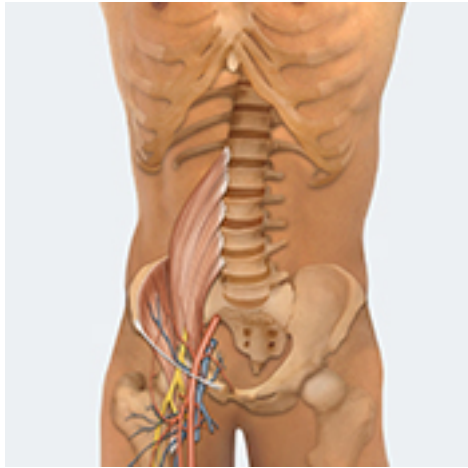m\_gluteus\_medius.tif



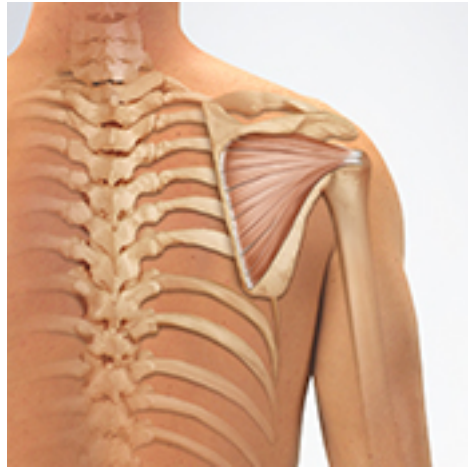m\_gluteus\_minimus.tif



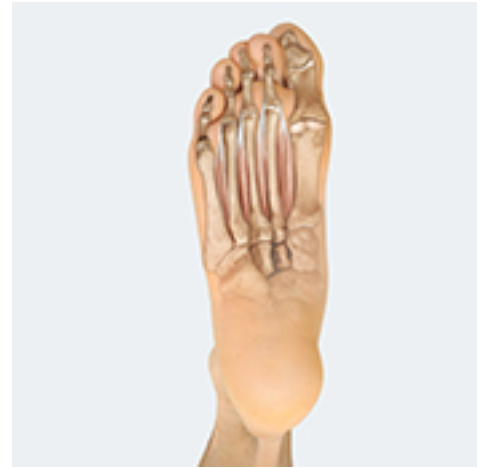m\_gracilis.tif



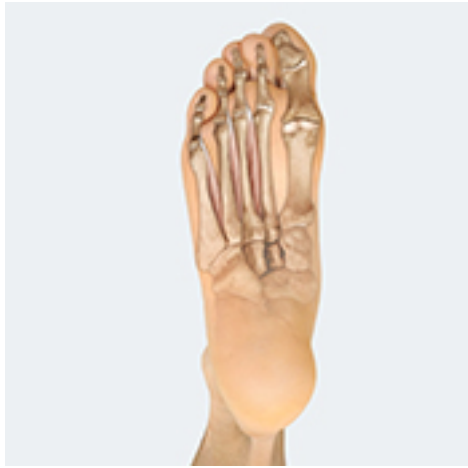m\_iliopsoas.tif



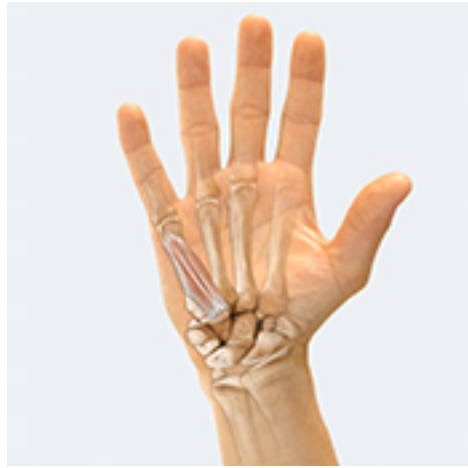m\_infraspinatus.tif



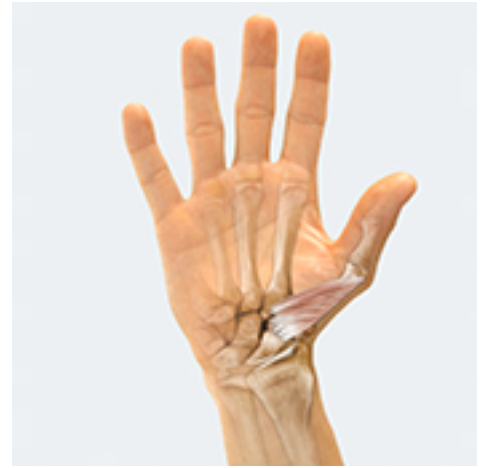m\_interossei\_dorsales\_pedis\_1\_4.tif



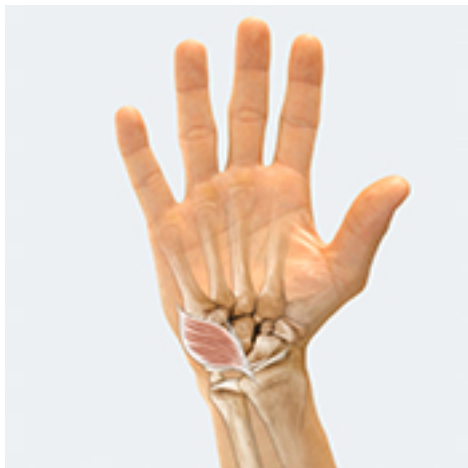m\_interossei\_plantares\_1\_3.tif



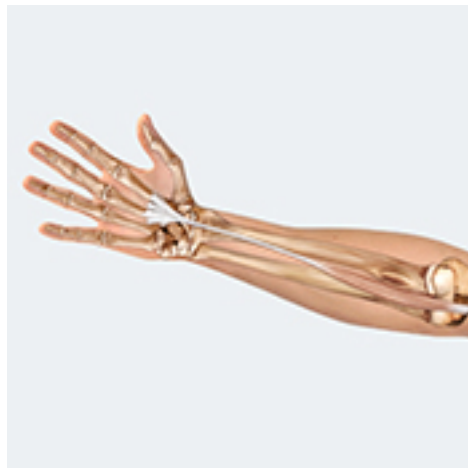m\_opponens\_digiti\_minimi.tif



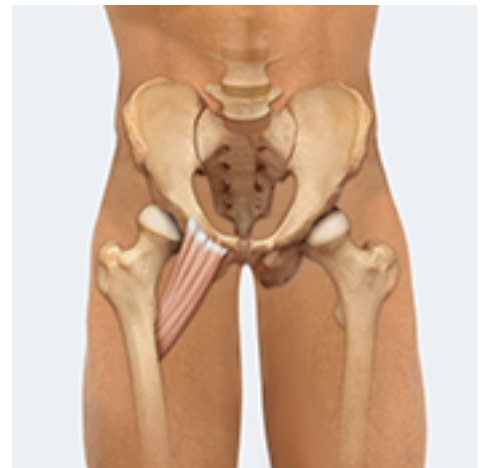m\_opponens\_pollicis.tif



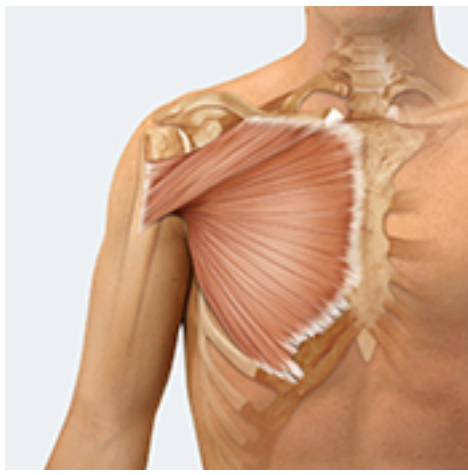
m\_palmaris\_brevis.tif



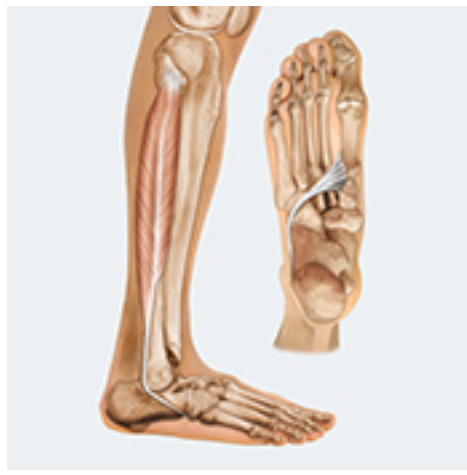m\_palmaris\_longus.tif



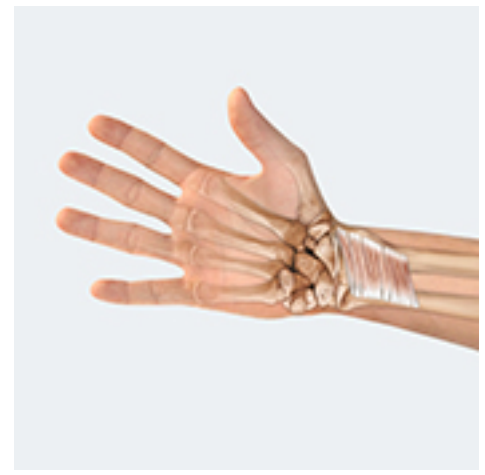m\_pectineus.tif



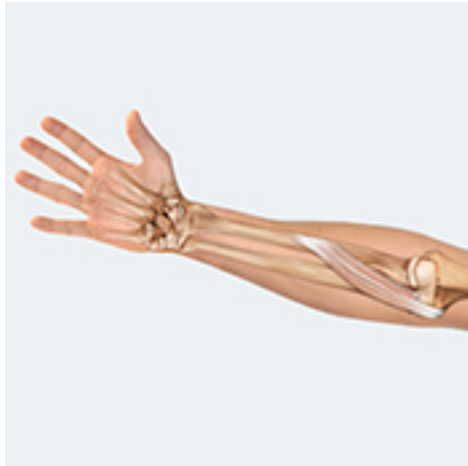m\_pectoralis\_major.tif



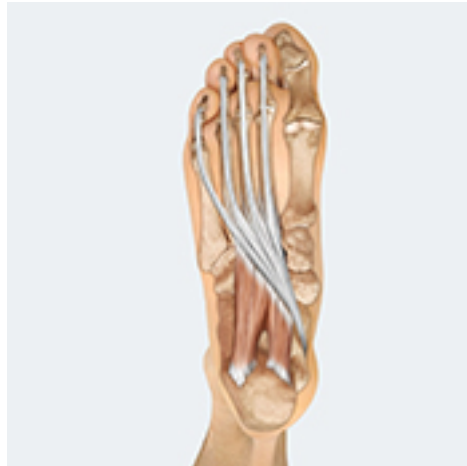m\_peroneus\_longus\_sehne.tif



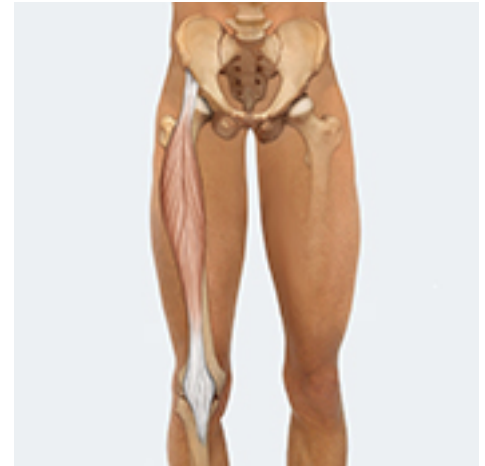
m\_pronator\_quadratus.tif



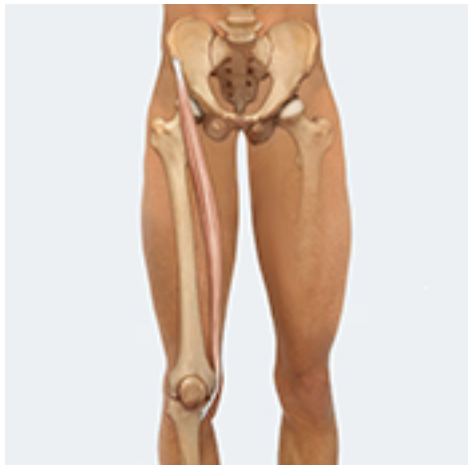
m\_pronator\_teres.tif



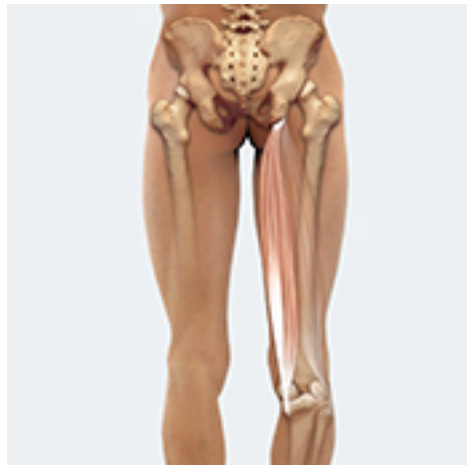
m\_quadratus\_plantae.tif



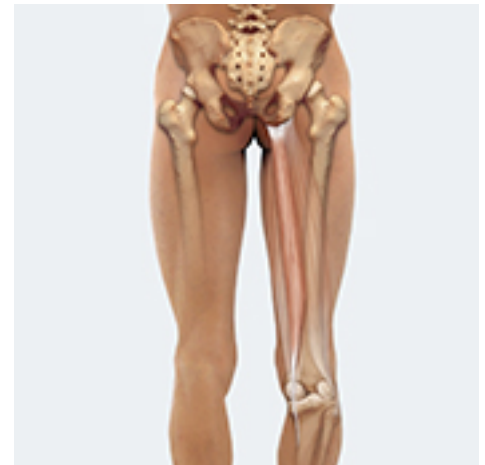
m\_rectus\_femoris.tif



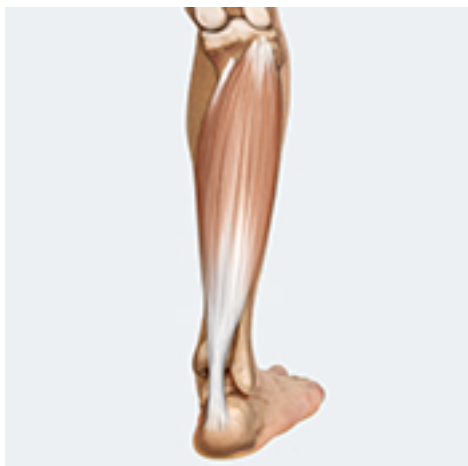
m\_sartorius.tif



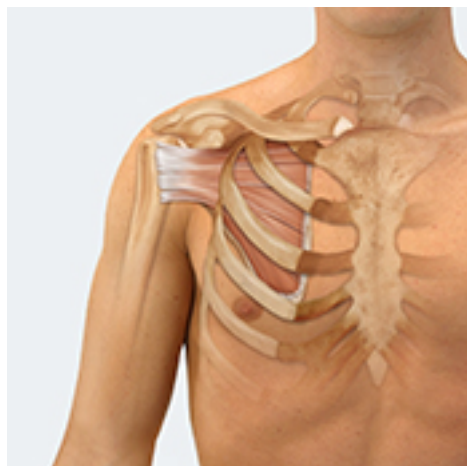m\_semimembranosus.tif



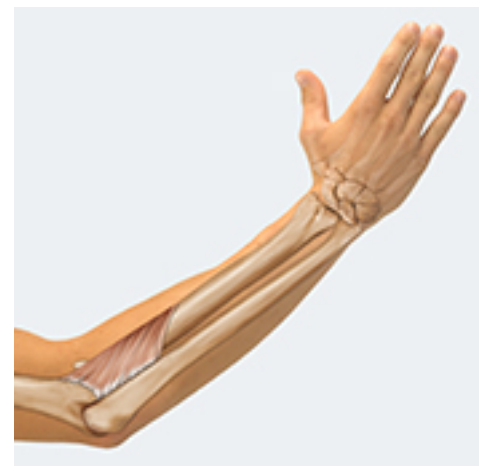m\_semitendinosus.tif



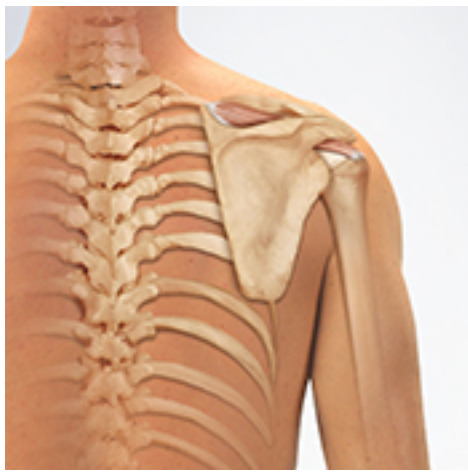m\_soleus.tif



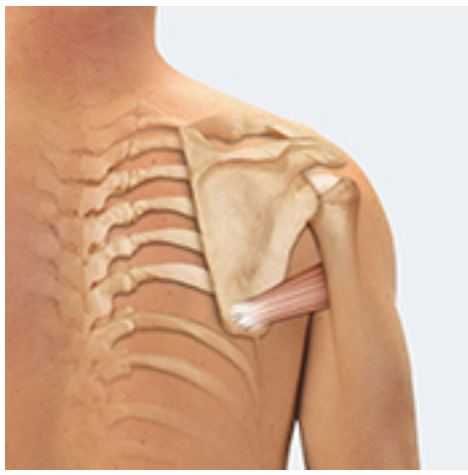m\_subscapularis.tif



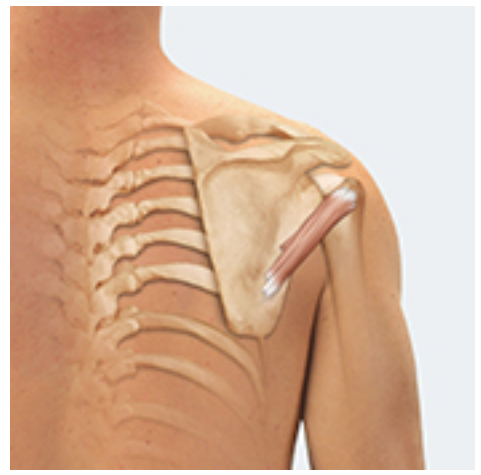m\_supinator.tif



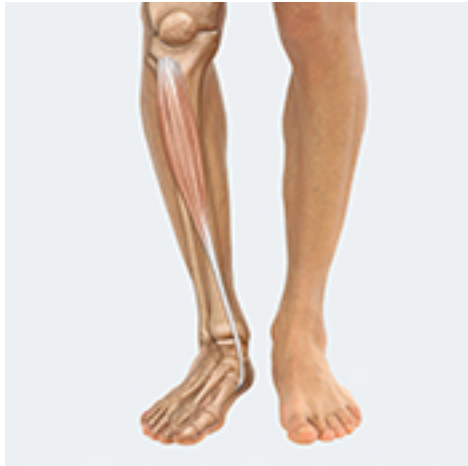m\_supraspinatus.tif



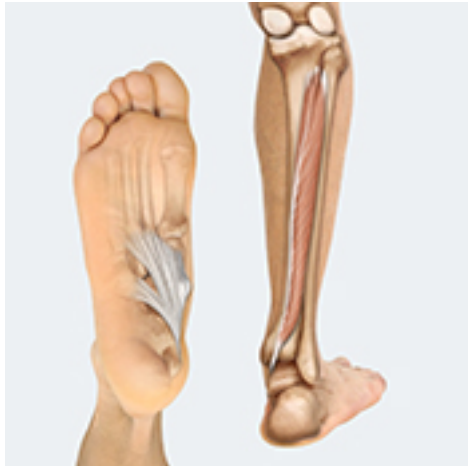
m\_teres\_major.tif



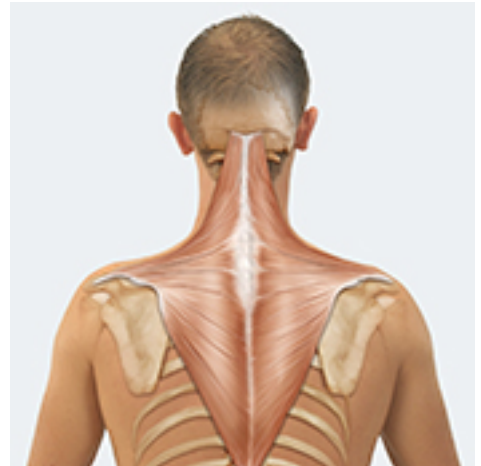m\_teres\_minor.tif



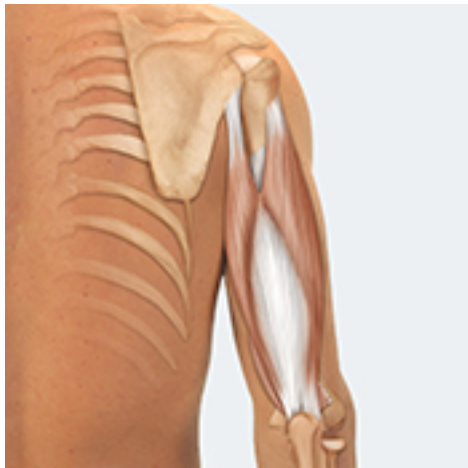m\_tibialis\_anterior.tif



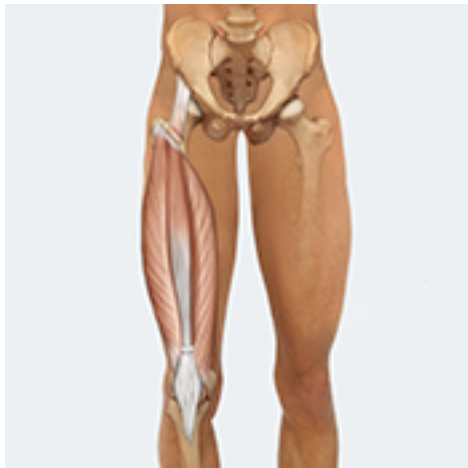
m\_tibialis\_posterior\_sehne.tif



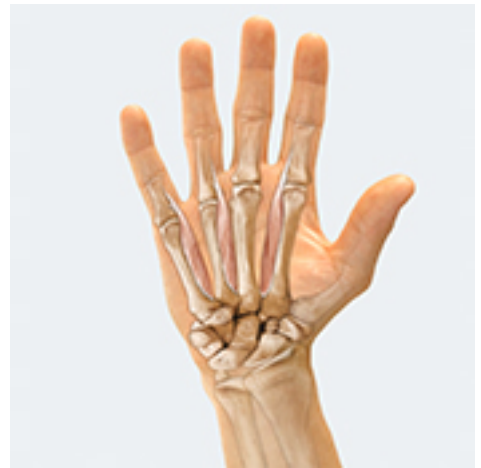m\_trapezius.tif



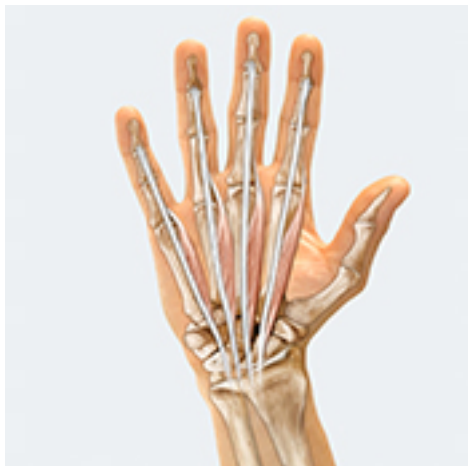m\_triceps\_brachii.tif



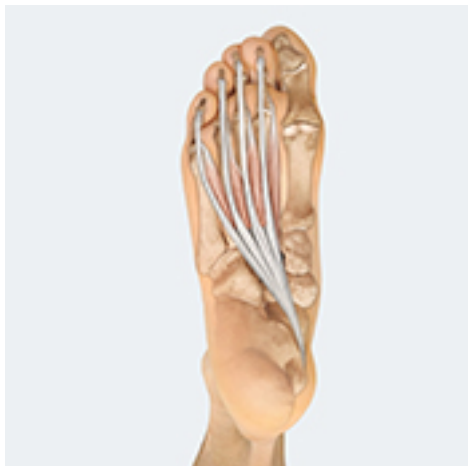
m\_vastus\_lateralis\_medialis\_intermedius...



mm\_interossei\_palmares.tif



mm\_lumbricales\_manus\_1\_4.tif



mm\_lumbricales\_pedis\_1\_4.tif